THE AMERICAN JOURNAL OF Gastroenterology

Endoscopic Application of Ankaferd Blood Stopper® as a Novel Experimental Treatment Modality for Upper Gastrointestinal Bleeding - a Case Report.

Journal:	*American Journal of Gastroenterology*
Manuscript ID:	AJG-08-0346
Manuscript Type:	Letter to the Editor
Keywords:	Ankaferd Blood Stopper, Gastrointestinal Bleeding
Manuscript Section:	Endoscopy

scholarONE™ Manuscript Central

LETTER TO THE EDITOR

Endoscopic Application of *Ankaferd* Blood Stopper® as a Novel Experimental Treatment Modality for Upper Gastrointestinal Bleeding - a Case Report.

Mevlut Kurt MD[1], Selcuk Disibeyaz MD[1], Meral Akdogan MD[1], Nurgul Sasmaz MD[1], Salih Aksu MD[2], İbrahim Celalettin Haznedaroglu MD[2]

[1]Department of Gastroenterology, Turkiye Yuksek Ihtisas Hospital, Ankara, Turkey

[2]Department of Hematology, Hacettepe University Medical Faculty, Ankara, Turkey

Key words: Ankaferd Blood Stopper, Gastrointestinal Bleeding

Corresponding Author: Mevlut Kurt MD

Department of Gastroenterology,

Turkiye Yüksek Ihtisas Hospital,

Sıhhiye, Ankara, Turkey

Tel:+090-505-2762812

e-mail: mevlutkurt2002@yahoo.com

For Peer Review

Endoscopic Application of *Ankaferd* Blood Stopper® as a Novel Experimental Treatment Modality for Upper Gastrointestinal Bleeding - a Case Report.

Ankaferd® is a unique medicinal plant extract, which has historically been used in Turkish traditional medicine as a hemostatic agent [1]. *Ankaferd* Blood Stopper® (ABS) as a medicinal product has been approved in the management of external hemorrhage and dental surgery bleedings in Turkey based on the safety and efficacy reports indicating its sterility and non-toxicity (*www.ankaferd.com*). *Ankaferd* comprises a standardized mixture of the plants *Thymus vulgaris*, *Glycyrrhiza glabra*, *Vitis vinifera*, *Alpinia officinarum* and *Urtica dioica*. The basic mechanism of action for *Ankaferd* is the formation of an encapsulated protein network that provides focal points for vital erythrocyte aggregation. *Ankaferd*–induced protein network formation with blood cells particularly erythrocytes covers the primary and secondary hemostatic system without disturbing individual coagulation factors [1].

A 52-year-old man had undergone Whipple's resection with the diagnosis of stage IIB (T2N1M0) distal cholangiocarcinoma in December 2006 at our hospital. He subsequently received six cycles of chemotherapy. He was then lost to follow-up until January 2008, at which he admitted to the emergency room with severe upper gastrointestinal bleeding that required the transfusion of 6 units of erythrocyte suspension. He underwent upper gastrointestinal endoscopy (25.01.2008) which showed an afferent loop with blood and with adherent clot on an ulcerated stoma at the site of hepatico-jejunostomy anastomosis (HJA). Endoscopic intervention was performed with epinephrine injection and argon plasma coagulation. However, these interventions failed achieve optimal bleeding control. Follow-up hemoglobin levels continued to drop from 11.4 g/dl to 9,0 g/dl within 6 days (Figure 1). A repeated upper endoscopy (31.01.2008) showed signs of recent bleeding with the presence of dark

For Peer Review

clots and coffee-ground blood distal to the gastro-jejunostomy anastomosis, with no active bleeding from the ulcerated stoma of the HJA. With a suspicion of local recurrence, multiple biopsies were obtained. Anticipating bleeding, informed consent regarding the experimental nature of the ABS as means of attaining hemostasis was obtained prior to the procedure. To control the bleeding from the biopsy site, 15 ml of ABS were applied topically, which produced immediate results. (Figure 2 Upper (A) and Lower (B) Panels). Follow-up hemoglobin levels are depicted in Figure 1. There were no findings consistent with malignancy, and an upper endoscopy performed on 06.02.2008 did not reveal any stigmata of bleeding, after which the patient was discharged.

Hemoclips, injection therapy and thermocoagulation are the most commonly used types of endoscopic hemostasis for the control of gastrointestinal bleeding, but still there are the problems of re-bleeding, the need for surgery and mortality [2]. Bleeding due to peptic ulcer [3] and gastric varices [4] are also important especially in 'poor outcome' patients [5]. The effective management of the bleeding problem is particularly evident in patients with hereditary and acquired hemorrhagic diathesis including neoplasia and the use of anticoagulant, antihemostatic drugs [6,7].

The present observation regarding the hemostatic effects of the topical use of ABS in a case with upper GI bleeding opens the way for the design of future case-controlled clinical trials in a distinct setting of gastrointestinal bleeding. *Ankaferd*-induced formation of the protein network covers the entire physiological hemostatic process without affecting any particular clotting factor [1]. ABS may, therefore, be effective both in individuals with normal hemostatic parameters as well as in patients with deficient primary and/or secondary hemostasis

For Peer Review

REFERENCES

1. Goker H, Haznedaroglu IC, Ercetin S, et al. Haemostatic actions of the folkloric medicinal plant extract, Ankaferd blood stopper. J Int Med Res 2008;36:163-70.
2. Sung JJ, Tsoi KK, Lai LH, et al. Endoscopic clipping versus injection and thermo-coagulation in the treatment of non-variceal upper gastrointestinal bleeding: A meta-analysis. Gut 2007;56:1364-73.
3. Cho YK, Kim CS, Kim SY, et al. The hemostatic effect of endoscopic sodium hyaluronate injection in peptic ulcer bleeding. Hepatogastroenterology 2007;54:1276-9.
4. Javvaji S, Kumar A, Madan K, et al. Management of gastric variceal bleeding. Trop Gastroenterol 2007;28:51-7.
5. Imperiale TF, Dominitz JA, Provenzale DT, et al. Predicting poor outcome from acute upper gastrointestinal hemorrhage. Arch Intern Med 2007;167:1291-6.
6. Kadayifci A, Haznedaroglu IC, Savas MC. Risk of withdrawing chronic anticoagulation without antithrombotic prophylaxis. Am J Gastroenterol 1997;92:361-2.
7. Soylu AR, Buyukasik Y, Cetiner D, et al. Overt gastrointestinal bleeding in haematologic neoplasms. Dig Liver Dis 2005;37:917-22.

For Peer Review

LEGENDS FOR FIGURES:

Figure 1.

Hemoglobin levels of the patient during the clinical follow-up and managements including the topical use of *Ankaferd* via the endoscopic intervention (ABS).

Figure 2.

Upper Panel (A): Actively bleeding afferent loop with red blood and ulcerated stoma of hepaticojejunoanastomosis in the patient with operated distal cholangiocarcinoma.

Lower Panel (B): The topical use of *Ankaferd* via the endoscopic intervention completely controlled the bleeding within seconds.

For Peer Review

Figure 2. Hemoglobin levels during follow up

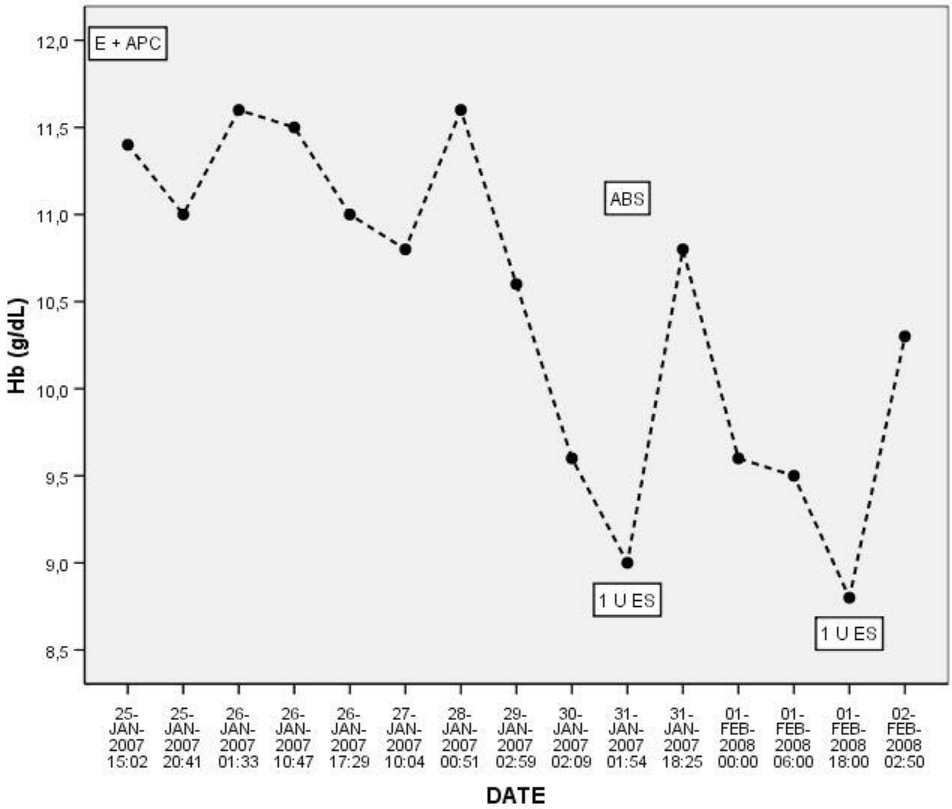

Abbreviations: E: Epinephrine, APC: Argon Plasma Coagulation, U ES: unit of Erythrocyte Suspension, ABS: Ankaferd blood stopper

Hemoglobin levels of the patient during the clinical follow-up and managements including the topical use of Ankaferd via the endoscopic intervention (ABS).
176x162mm (96 x 96 DPI)

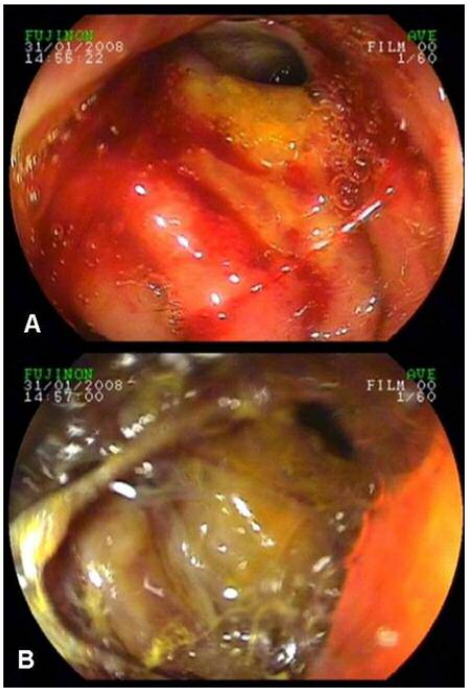

Upper Panel (A): Actively bleeding afferent loop with red blood and ulcerated stoma of hepaticojejunoanastomosis in the patient with operated distal cholangiocarcinoma. Lower Panel (B): The topical use of Ankaferd via the endoscopic intervention completely controlled the bleeding within seconds.
254x190mm (96 x 96 DPI)